


Case Report

Common Bile Duct Stricture & Prior Cholecystectomy

Helsinki University Hospital
Helsinki, Finland



ARCHIMEDES

Biodegradable Biliary and Pancreatic Stent

48 y/o female patient was presented with strictures in the common bile duct (CBD) due to prior cholecystectomy.

Patient had both plastic and self-expanding metallic stents (SEMS) placed previously and then subsequently removed. The stricture had been slightly dilated by the previous interventions, but not completely (image 1).

Doctors in Helsinki wanted to place an **ARCHIMEDES** biodegradable stent for the last treatment to fully dilate the lumen and to mitigate having to bring the patient back for yet another ERCP for stent removal.

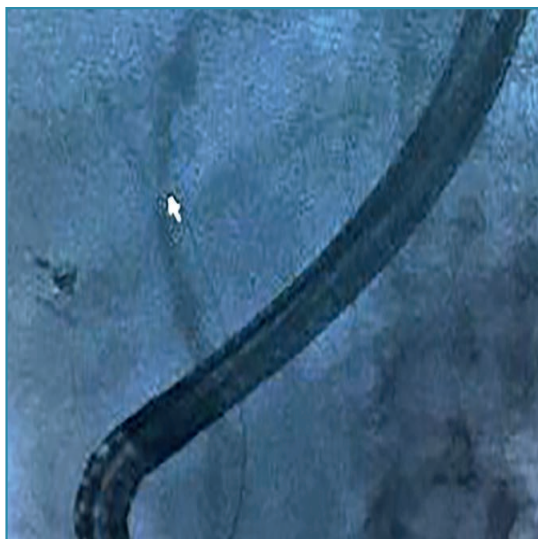


Image 1. Fluoroscopic view of contrast medium in the CBD highlighting the area of the stricture.



Image 2. Fluoroscopic view of the three (3) **ARCHIMEDES** stents placed in the CBD.

Case Report

Common Bile Duct Stricture & Prior Cholecystectomy

Helsinki University Hospital
Helsinki, Finland

Three (3) slow degrading **ARCHIMEDES** stents (10 F x 10 cm) were endoscopically placed across the stricture site. Image 2 shows the three (3) **ARCHIMEDES** stents in place alongside each other in the CBD.

Due to the biodegrading properties of the **ARCHIMEDES** stent, the doctors in Helsinki felt more comfortable placing the stents further into the CBD to ensure proper placement, utilizing both proximal and distal anti-migratory struts, without concern of later removal due to migration or occlusion.

The physicians were all pleased with the easy and successful placement of the first **ARCHIMEDES** stents in Finland. They commented that the three (3) **ARCHIMEDES** stent placements went smoothly and efficiently, with lead physician Dr. Leena Kylänpää, specifically calling attention to the procedural similarities to placing traditional plastic stents.

Pictured below are the doctors of the Helsinki University Hospital, including lead GI physician, Dr. Leena Kylänpää, the Director of Global Sales for amg GI, Shawn O'Brien, and Jorma Kinnunen of CardiRad Distributors.



Image 3. The entire team in Helsinki for the first placement of the **ARCHIMEDES** in Finland.



CE 1434

amginternational
A Q3 Medical Company

amg International GmbH | Boschstraße 16 | D-21423 Winsen | Germany

Phone +49 4171 6905 57-0
Fax +49 4171 6905 57-11

Email info@amggastro.com
Web www.amggastro.com



CREATING VALUE BY HELPING PEOPLE

CCR_BD_GI_BPS-E_006 - Helsinki_FN - Cholecystectomy & CBD Strictures - 2023-03
Made in Germany