

Case Report


Prophylaxis for PEP Post-Ampullectomy

IMAGE 2019 Live Endoscopy Course
Milan, Italy



ARCHIMEDES

Biodegradable Biliary and Pancreatic Stent



27 y/o female patient with a history of familial polyposis and prior total colectomy presented with 30 mm papillary adenomatous lesion (image 2) with extension into the third portion of the duodenum.

Image 1. Prof. Horst Neuhaus, Director of Endoscopy at the Evangelisches Krankenhaus Düsseldorf

Professor Horst Neuhaus, the Director of Endoscopy at the Evangelisches Krankenhaus Düsseldorf, expertly performed a resection of the adenomatous lesion, as well as an ampullectomy (image 5). An 0.035" floppy tip guidewire was placed into the pancreatic duct without contrast in preparation for stent placement (image 4).

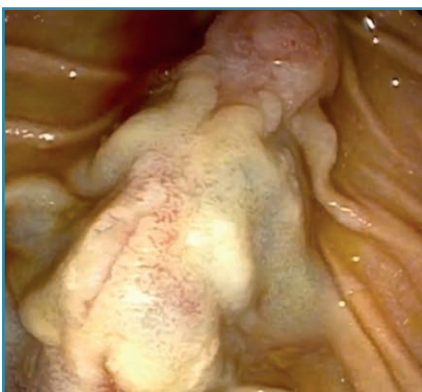

Image 2. Endoscopic view of the adenomatous lesion. The papillary orifice can be seen at the 12 o'clock position.

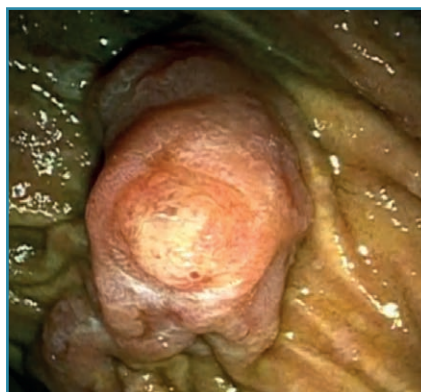

Image 3. Endoscopic view of the papillary orifice.

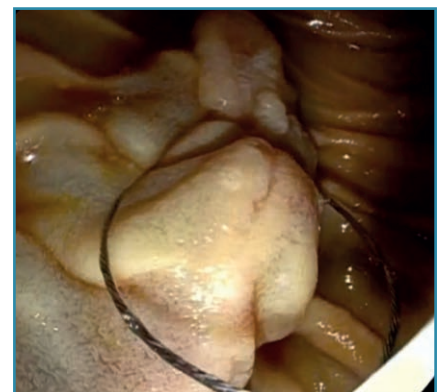

Image 4. Endoscopic view of resection of the distal portion of the adenomatous lesion using a snare.

Case Report

Prophylaxis for PEP Post-Ampullectomy

IMAGE 2019 Live Endoscopy Course
Milan, Italy

Prof. Neuhaus prepared an **ARCHIMEDES** biodegradable stent per the included instructions for use (IFU) and implanted a 6 F x 6 cm fast degrading pancreatic stent, over-the-wire, into the pancreatic duct with complete ease and technical success (image 8 & 9).

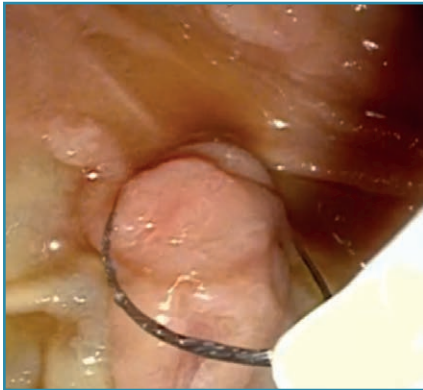


Image 5. Endoscopic view of the ampullectomy utilizing a snare.

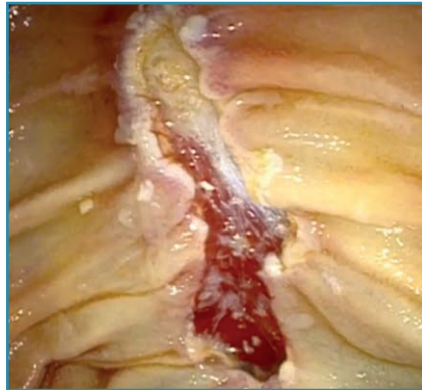

Image 6. Endoscopic view of the resected adenomatous lesion and ampulla.

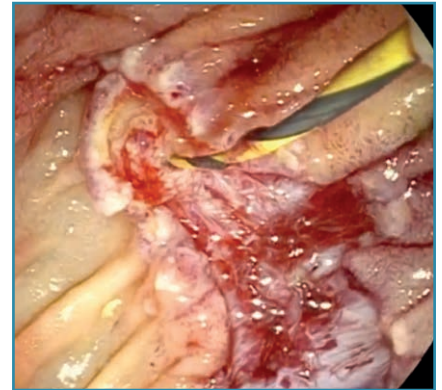


Image 7. Guidewire inserted into the pancreatic duct.

The distal (split tail) portion of the **ARCHIMEDES** full biodegradable pancreatic stent was left out in the duodenum (image 10) and the case was concluded without further issue.

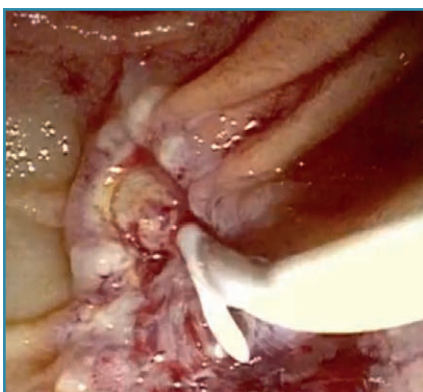


Image 8. ARCHIMEDES biodegradable pancreatic stent being insert over-the-wire into the pancreatic duct.

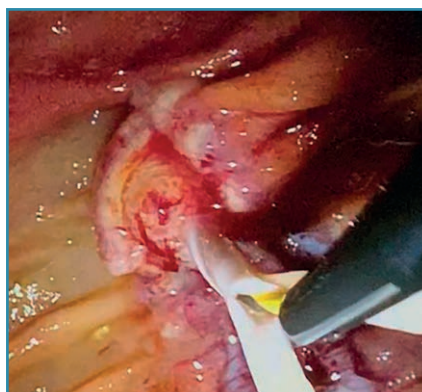

Image 9. ARCHIMEDES biodegradable pancreatic stent seen being pushed into its final position. Note the split tail design of the 6 F pancreatic stent.

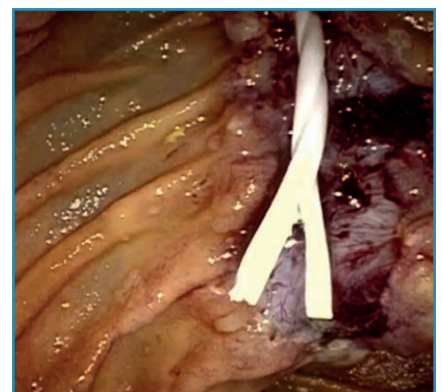


Image 10. ARCHIMEDES biodegradable pancreatic stent in final position. Note the helical design visible on the body of the stent.



CE 1434

amginternational
A Q3 Medical Company

amg International GmbH | Boschstraße 16 | D-21423 Winsen | Germany

Phone +49 4171 6905 57-0
Fax +49 4171 6905 57-11

Email info@amggastro.com
Web www.amggastro.com



CREATING VALUE BY HELPING PEOPLE

CCR_BD_GL_BPS-E_010 - Milan_IT - PEP Post Ampullectomy - 2023-03
Made in Germany