

Case Report

Cystic Duct Leak & Prophylaxis for PEP

Ordensklinikum Linz
Linz, Austria



ARCHIMEDES

Biodegradable Biliary and Pancreatic Stent

During a live case presentation during the Clinical Immersion-Expert Meeting in Endoscopy held in Linz, Austria at the Ordensklinikum Linz, Dr. Georg Spaun and Dr. Alexander Ziachehabi successfully placed the **ARCHIMEDES** biodegradable biliary/pancreatic stent in 51 y/o male patient with a prior cholecystectomy to treat an unresolved cystic duct leak.

The patient had previously been treated with two (2) plastic stents in an attempt to treat the leak and the possibility of post-ERCP pancreatitis (PEP). The physicians opted to remove the plastic stents and place a single 10 F x 8 cm **ARCHIMEDES** biodegradable biliary/pancreatic to treat both the leak and the possibility of post-ERCP pancreatitis due to the repeated access through the papilla to remove the plastic stents.

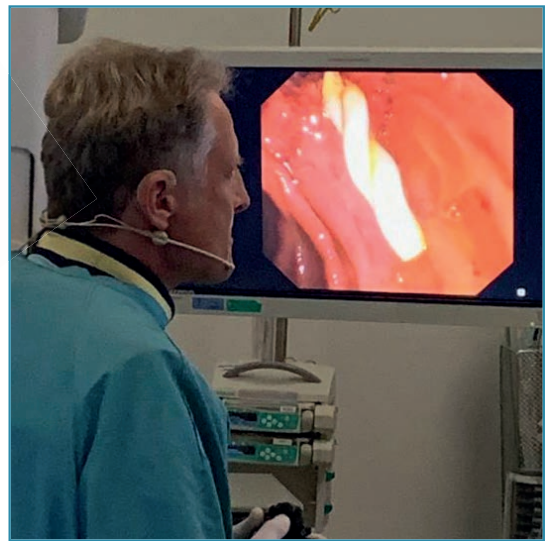

Image 1. Dr. Georg Spaun visualizing the final position of the **ARCHIMEDES** stent placed during a live case presentation in Linz, Austria.

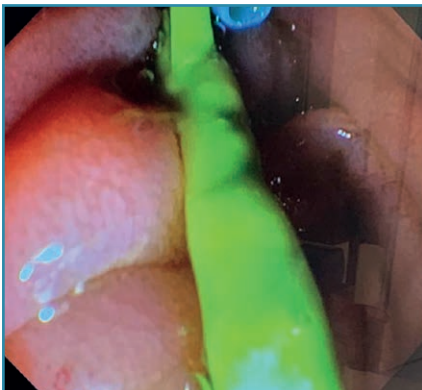


Image 2. Endoscopic view of two (2) plastic stents already in place, which had to be removed.

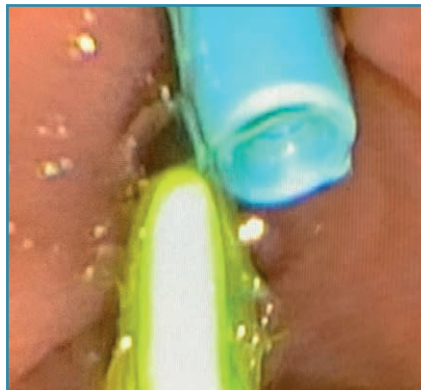


Image 3. Endoscopic view of secondary, more proximal plastic stent (light blue)



Image 4. Endoscopic view of the retrieval of the second plastic stent (blue) using a snare

Case Report

Cystic Duct Leak & Prophylaxis for PEP

Ordensklinikum Linz
Linz, Austria

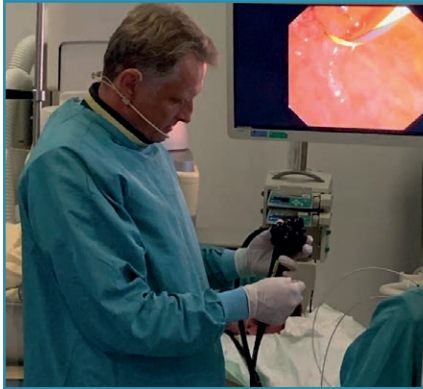

Image 5. Dr. Spaun expertly introducing an 0.035" guidewire into the endoscope just prior to **ARCHIMEDES** stent placement.

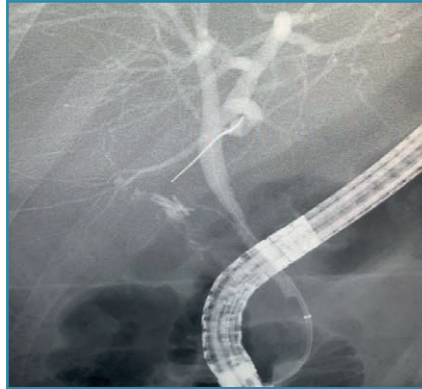


Image 6. Fluoroscopic visualization of the guidewire being positioned through the papilla and into the common bile duct (CBD).

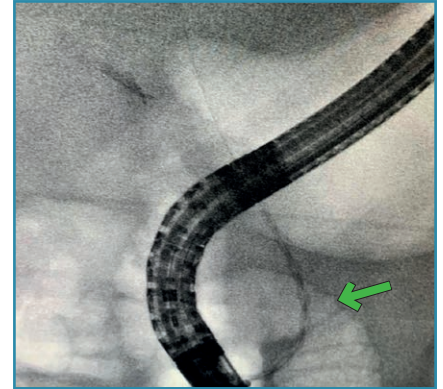


Image 7. Fluoroscopic view of the **ARCHIMEDES** stent being placed over-the-wire into the CBD (green arrow)

The stent can clearly be seen due to the barium sulfate.

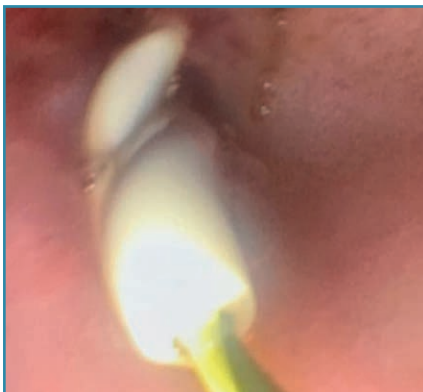

Image 8. Endoscopic view of the distal portion of the **ARCHIMEDES** stent extended out of the papilla into the duodenum.

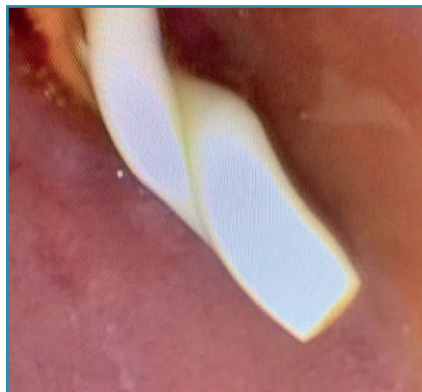

Image 9. Endoscopic view showing the final position of the **ARCHIMEDES** stent with the guidewire removed.

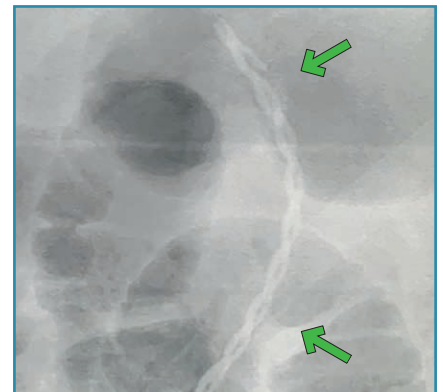


Image 10. Fluoroscopic view of the **ARCHIMEDES** stent in its final position (green arrows).



CE 1434

amginternational
A Q3 Medical Company

amg International GmbH | Boschstraße 16 | D-21423 Winsen | Germany

Phone +49 4171 6905 57-0
Fax +49 4171 6905 57-11

Email info@amggastro.com
Web www.amggastro.com



CREATING VALUE BY HELPING PEOPLE

CCR_BD_GI_BPS-E_011 - Linz_AT - Cystic Duct Leak & PEP - 2023-03
Made in Germany