

# Special Case Report

## Prophylaxis for Liver Transplant Anastomosis

University General Hospital Gregorio Marañón  
Madrid, Spain



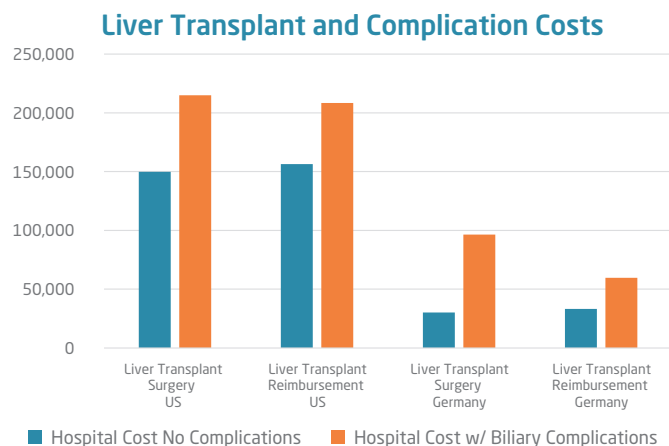
# ARCHIMEDES

Biodegradable Biliary and Pancreatic Stent

The World's Only CE Approved Biodegradable Biliary/Pancreatic Stent

The **ARCHIMEDES** Biodegradable Biliary and Pancreatic Stent achieved another clinical milestone as it was utilized for the first time in an Orthotopic Liver Transplant (OLT) surgical case, in order to, prophylactically minimize the negative effects of a possible bilio-biliary anastomotic complication (I.E. a stricture or leak) formed post-OLT procedure. Orthotopic liver transplantation (OLT), which was once considered an experimental procedure, is now the treatment of choice for selected patients with end-stage liver disease or acute liver failure. OLT currently has a 5-year survival of 70-80% and generally provides a good quality of life (QoL). Globally, it is estimated that over 45,000 annual liver transplants are performed annually and this number can be doubled or tripled for other modified anatomy procedures such as a Whipple and biliary diversions which also could benefit from the prophylactic use of the **ARCHIMEDES** Biodegradable stent in lieu of traditional surgical procedures or the use of plastic biliary stents.

Biliary complications after liver transplantation remain common. A study published in the *American Journal of Transplantation 2016; 16: 594-602* showed that at least one complication occurred in 70% of Deceased Donor Liver Transplants (DDLT's) and 73% Live Donor Liver Transplants (LDLTs), respectively, highlighting the challenges of liver transplantation.<sup>1</sup> They can occur in the immediate post-liver transplant period, as well as later in time, during recovery of the transplant. Often, particularly in the immediate post-transplant period, technical aspects of the operation and vascular insufficiency are the leading causes of those complications.<sup>2</sup>



Both endoscopic and percutaneous methods can be useful in the subsequent management of these complications or, in certain situations, as a bridge to definitive surgical therapy. The article described the probability of specific complications in recipients of deceased or living donor liver transplantation in the first year, overall, to be as follows for Biliary related complications only: Bile leak/biloma 26%, Biliary stricture 32%, and Biliary tree infection 14%.<sup>3</sup>

# Special Case Report

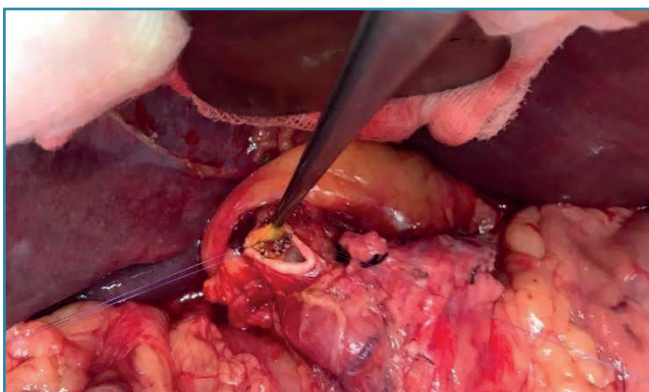
## Prophylaxis for Liver Transplant Anastomosis

University General Hospital Gregorio Marañón  
Madrid, Spain

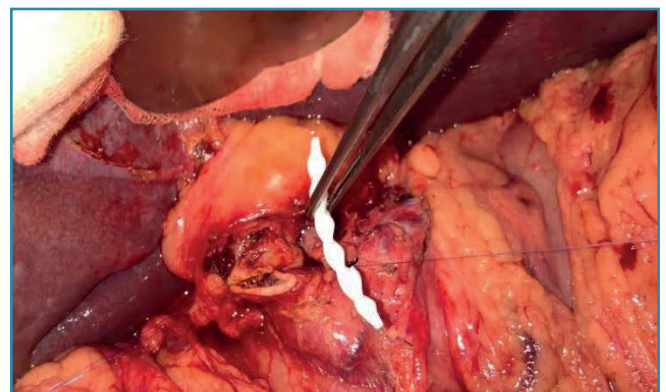Based on a publication in the *Ann Transplant 2010* discussing “*The Cost of Graft Failure and Other Severe Complications after Liver Transplantation*” - Experience of a German transplant centre showed the the mean cost of OLT was Euro 52,570 (range 18,330-397,450) in Germany and can be doubled or tripled for other OCED. Post-transplant complications significantly raised cost, with an increase of **62% by vascular complications, 175% by renal failure, 207% by biliary leakage, 227% by graft failure and 234% by sepsis**. Additional analysis revealed reoperation, hypotension, and graft failure as independent cost factors. Graft failure contributed for mean additional costs of 105,911 Euro. In particular, the cost of ICU therapy increased from 16,884 Euro up to 92,239 Euro. The conclusions showed that graft failure was identified as the major cost-determining factor. The cost impact of post-transplant complications is mainly caused by the length of stay. **In a study completed by the University of Michigan Department of Surgery, Division of Transplantation, University of Michigan Health System, Ann Arbor, Michigan, USA and the Department of Surgery, Division of Transplantation, Beth Israel-Deaconess Medical Center, Harvard Medical School, Boston, Massachusetts, USA: Who pays for biliary complications following liver transplant?** A business case for quality improvement, clearly showed that biliary complications are a main drive for increased cost to the hospital and payer. Remarkably, reimbursement by the payer to the physicians and medical center was \$55,362 higher in patients with a biliary complication.

To minimize the negative impact of those biliary complications, some Liver Transplant Teams have tried numerous techniques to try to avoid or prevent such complications, including the use of silastic or rubber T-Tube, which is positioned at the bilio-biliary anastomotic site, re-connecting the biliary duct. This brings about its own inherent complications, especially with retreatment and removal of the device. In this historic **ARCHIMEDES** case, the **ARCHIMEDES** Biodegradable Biliary and Pancreatic Stent, with a Medium degradation profile, was used as an alternative to minimize the current risk of biliary complications with liver transplant procedures. Due to the biodegradable characteristics of this novel **ARCHIMEDES** stent, with its helical outer construct that allows for the ease of fluid flow and the potential for tension support on the anastomotic site, it has the potential to reduce biliary leaks, strictures, and infections, with the added benefit of to eliminate the need for device retrieval and associated complications avoiding subsequent procedure (endoscopic, percutaneous or surgical).

In this particular first OLT procedure where **ARCHIMEDES** Biodegradable Biliary and Pancreatic Stent was used, it was performed at the Liver Transplant and Hepato-Biliopancreatic Surgery Section of the General Surgery Department, University General Hospital Gregorio Marañón, in Madrid, Spain. Although much more clinical work is needed, there is optimism that this next generation biodegradable device, the **ARCHIMEDES** can assist in reducing the complications for these critically ill patients, while improving their quality of life, and reducing the overall cost of care through better efficacy.



**Image 1.** Biliary duct of receptor (14mm). It should be noted that a mismatch of the receptor duct and the implant if not properly matched may lead to additional increased complications. Notice the placement of the posterior sutures for gentle countertraction for the device insertion.



**Image 2.** The **ARCHIMEDES** biodegradable stent (10 F x 40 mm Medium degradation profile) just prior being introduced at the bilio-biliary anastomotic site. Notice the posterior anastomotic sutures in place and the suture being used for traction to ensure proper approximation of the ducts before implanting the Archimedes Biodegradable Implant and prior to completion of the full anastomosis.

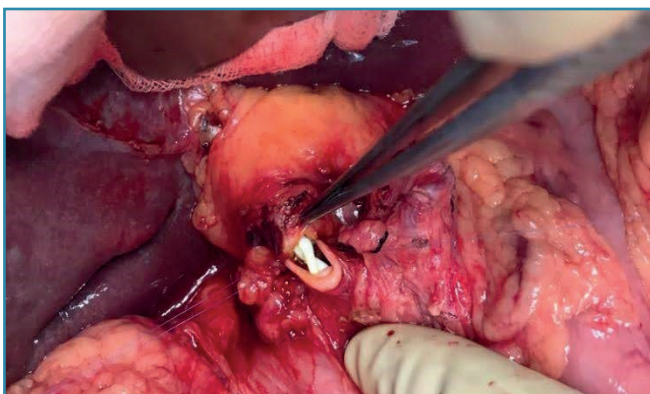
# Special Case Report

## Prophylaxis for Liver Transplant Anastomosis

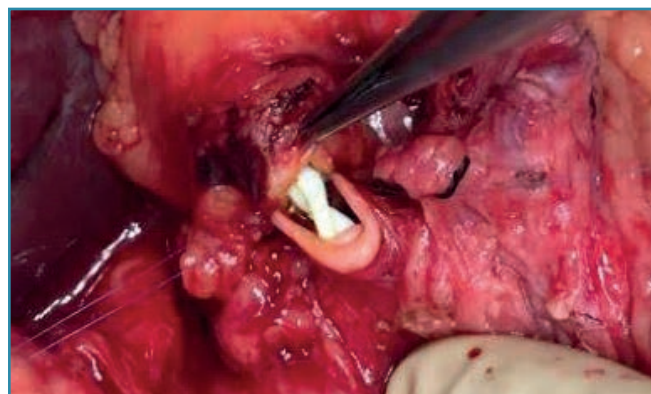
University General Hospital Gregorio Marañón  
Madrid, Spain

Further OLT cases are expected to take place with the use of **ARCHIMEDES** Biodegradable Biliary and Pancreatic Stent under a Pilot Study setting with additional sites being added globally. As the need expands it is envisioned that the prophylactic stenting will not address the total issues associated with liver transplantations and that a more traditional balloon expandable biodegradable stent will be required for patients needing large biliary support devices post-surgical complications.

The **UNITY Biliary** (UNITY-B) Biodegradable Balloon Expandable Implant is focused on biliary and pancreatic drainage and is currently being trialed with estimated approval in mid-2020. With its patented magnesium alloy and polymer coating the Unity Devices are designed to utilize the best attributes of both materials. In addition, the **UNITY Peripheral** (UNITY-P) Biodegradable Balloon Expandable Implant will be trialed for peripheral indications finally giving surgeons and interventionalist the device portfolio they need to assist in the reduction of complications, the improvement of outcomes, and the over all reduction of the cost of the procedures.



**Image 3.** View of **ARCHIMEDES** biodegradable stent in position, just prior completion of the anterior suturing of the bilio-biliary anastomosis.



**Image 4.** Close up of the medial aspect of the **ARCHIMEDES** implant with helical design visible.

<sup>1</sup> M.J. Englesby, et al. Who Pays For Biliary Complications Following Liver Transplants " A Business Case for Quality Improvement"; American Journal of Transplantation 2006.

<sup>2</sup> Luciano Bertocco De Paiva Hadaad, et al. Predictors of Micro-costing Components in Liver Transplantation; Clinics 72(6):333-342 · June 2017.

<sup>3</sup> B. Samstein, et al. Complications and Their Resolution in Recipients of Deceased and Living Donor Liver Transplants: Findings from the A2ALL Cohort St.; American Journal of Transplantation 2016; 16: 594-602.

<sup>4</sup> Yohan Friso Lock, et al. The Cost of Graft Failure and Other Severe Complications After Liver Transplantation - experience from a German Transplant Center; Ann Transplant, 2010; 15(3): 11-18.

<sup>5</sup> B. Samstein, et al. Complications and Their Resolution in Recipients of Deceased and Living Donor Liver Transplants: Findings from the A2ALL Cohort St.; American Journal of Transplantation 2016; 16: 594-602.

<sup>6</sup> Sjoerd de Rave, et al. Heterotopic vs. Orthotopic Liver Transplantation for Chronic Liver Disease: A Case-Control Comparison of Short-Term and Long-Term Outcomes; Liver Transplantation 11(4):396-401 · April 2005.



CE 1434

**amg**international  
A Q3 Medical Company

**amg International GmbH** | Boschstraße 16 | D-21423 Winsen | Germany

Phone +49 4171 6905 57-0

Email info@amggastro.com

Fax +49 4171 6905 57-11

Web www.amggastro.com