

# Case Report

Humanitas Research Hospital  
Milan, Italy

THE FUTURE IN  
**BIORESORBABLE**  
GI PRODUCTS

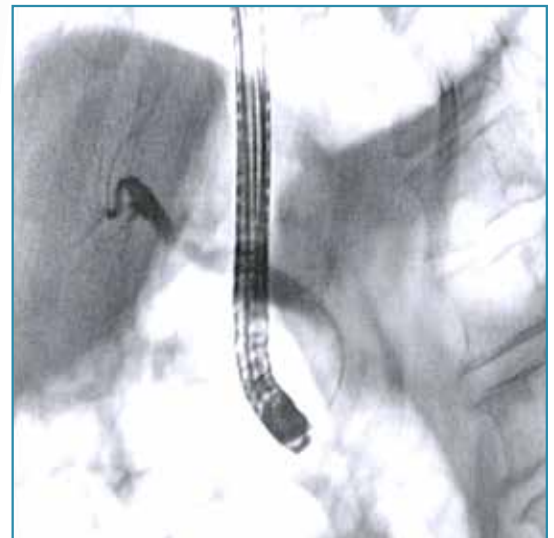## ARCHIMEDES

Biodegradable Biliary and Pancreatic Stent

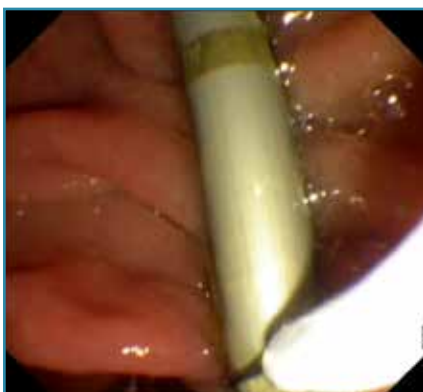

68 y/o male patient with previous choledocholithiasis and plastic stent placement. Presented with stenosis at the distal portion of the common bile duct (CBD).

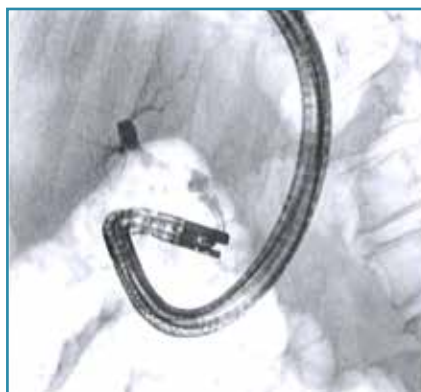ERCP performed to assess and remove plastic stent, attempt to eliminate small stones, and place bioresorbable stent. A 10 F standard plastic stent that had been placed previously was removed using endoscopic biopsy forceps. Additionally, several small stones and debris were removed from the CBD and in order to provide continued drainage and maintain patency, an **ARCHIMEDES** fully biodegradable biliary stent (10 F x 80 mm, slow degradation) was implanted in the CBD in transpapillary position.



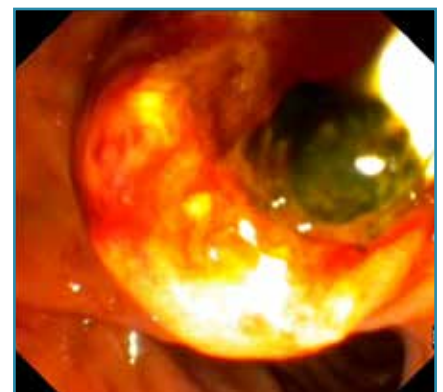
**Image 1.** Fluoroscopic image showing stenosis at the distal portion of the CBD.



**Image 2.** Endoscopic retrieval of previously implanted standard plastic stent



**Image 3.** Fluoroscopic view of CBD showing also some residual gallbladder sludge and small gallstones



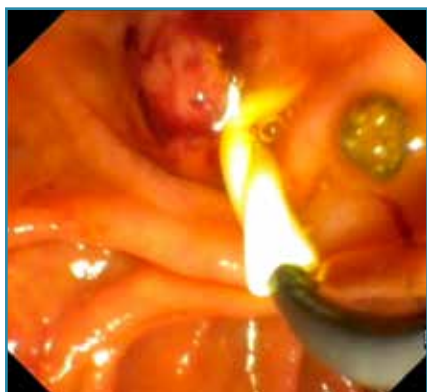**Image 4.** Endoscopic view of a small gallstone already at papillary level

# Case Report

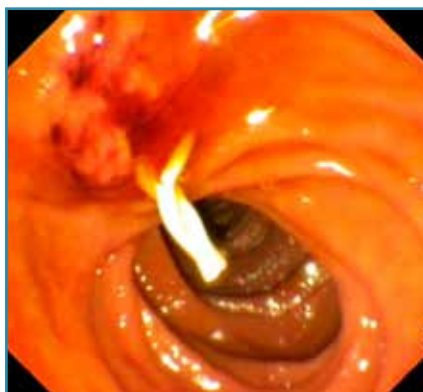Humanitas Research Hospital  
Milan, Italy

The **ARCHIMEDES** biodegradable stent was prepared per the included instructions for use (IFU) and implanted in the CBD, over a 0.035" guidewire, along with a pusher, with complete success.

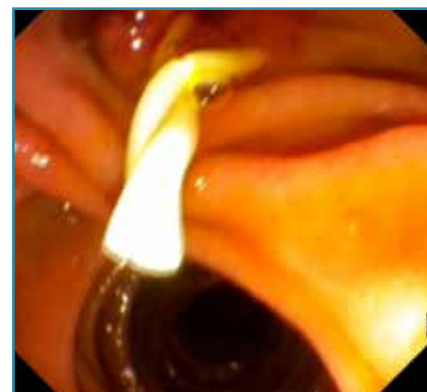The technique for implantation was similar to the technique used for standard plastic stents making it easy for the physician and staff to adopt the new technology.



**Image 5.** Transpapillary introduction of the **ARCHIMEDES** biodegradable biliary stent

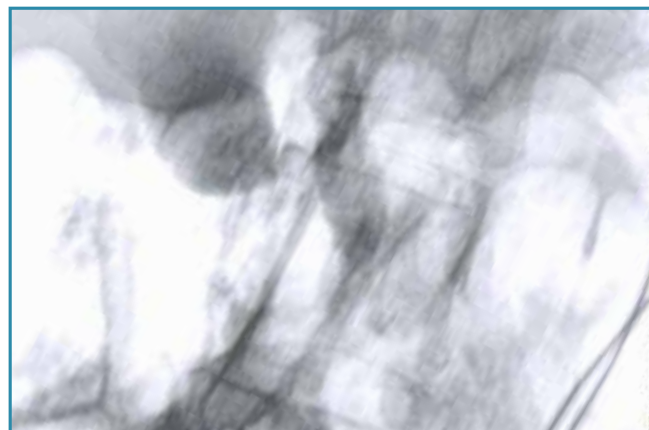


**Image 6.** **ARCHIMEDES** biodegradable biliary stent, clearly showing the duodenal flap



**Image 7.** Additional view of the distal portion of the **ARCHIMEDES** biodegradable biliary stent in the duodenum

For staff training and educational purposes the distal most portion of the **ARCHIMEDES** biodegradable stent was left in the duodenum, however, the doctor mentioned he could have implanted totally at the CBD level without any concerns due to the biodegradable nature of the new technology.



**Image 8.** Final fluoroscopic view of the **ARCHIMEDES** biodegradable biliary stent implanted

**amg**international  
A Q3 Medical Company

**amg International GmbH** | Boschstraße 16 | D-21423 Winsen | Germany

Phone +49 4171 6905 57-0  
Fax +49 4171 6905 57-11

Email [info@amggastro.com](mailto:info@amggastro.com)  
Web [www.amggastro.com](http://www.amggastro.com)

Manufactured by  
QualiMed Innovative Medizinprodukte GmbH  
Boschstraße 16 | D-21423 Winsen | Germany | [www.qualimed.de](http://www.qualimed.de)

Humanitas Case 1  
Rev.01 10-2018