

Case Report

Humanitas Research Hospital
Milan, Italy

THE FUTURE IN
BIORESORBABLE
GI PRODUCTS

ARCHIMEDES

Biodegradable Biliary and Pancreatic Stent

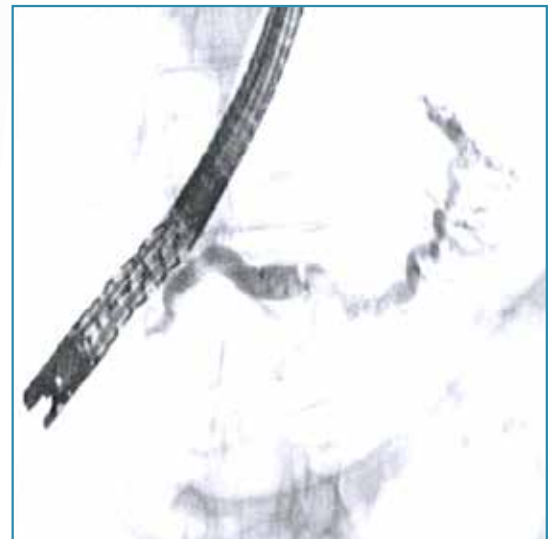

Image 1. Fluoroscopic image showing Pancreatic duct with stenosis

65 y/o female patient with chronic pancreatitis attributed to a pancreas divisum and pancreatic duct stenosis. ERCP performed to evaluate and assess for sphincterotomy and stenting.

Papilla of Santorini was enlarged via sphincterotomy. Pancreatic duct (PD) was assessed and an **ARCHIMEDES** biodegradable stent (8 F x 80 mm, slow degradation) was implanted to support the treatment of the stenosis.

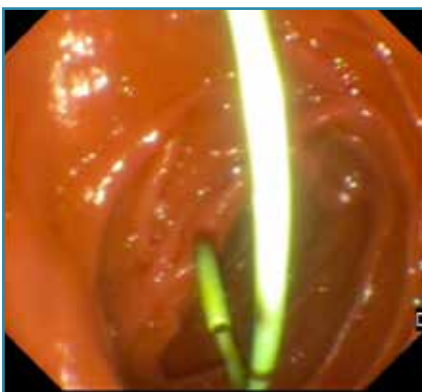


Image 2. Endoscopic view of the cannulation of the papilla of Santorini

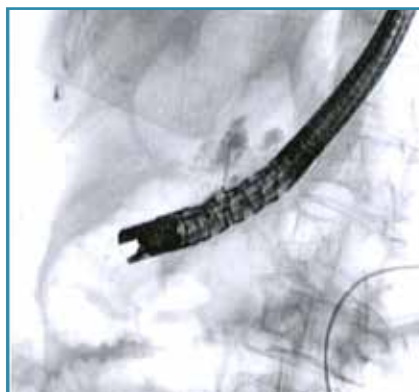

Image 3. Fluoroscopic view of duct coming from the papilla of Santorini

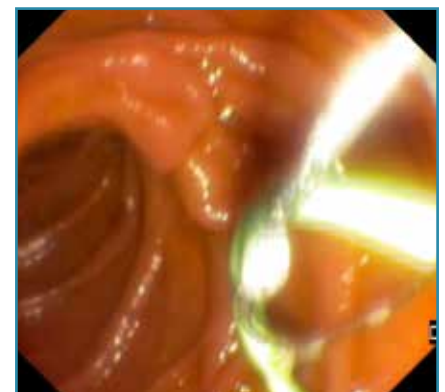


Image 4. Moment of the sphincterotomy of the minor papilla

Case Report

Humanitas Research Hospital
Milan, Italy

The **ARCHIMEDES** biodegradable stent was prepared per the included instructions for use (IFU) and implanted in the PD, over a 0.035" guidewire, along with a pusher, with complete success. The technique for implantation was similar to the technique used for standard plastic stents making it easy for the physician and staff to adopt the new technology.

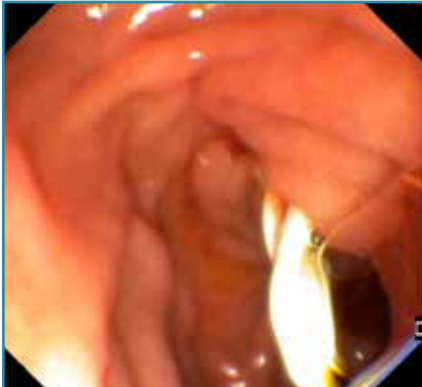

Image 5. ARCHIMEDES biodegradable pancreatic stent being introduced (first position), transpapillary

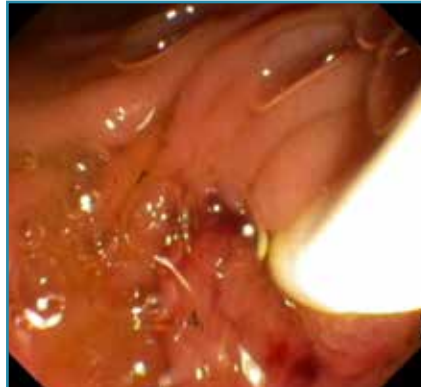

Image 6. ARCHIMEDES biodegradable pancreatic stent being introduced (first position), transpapillary

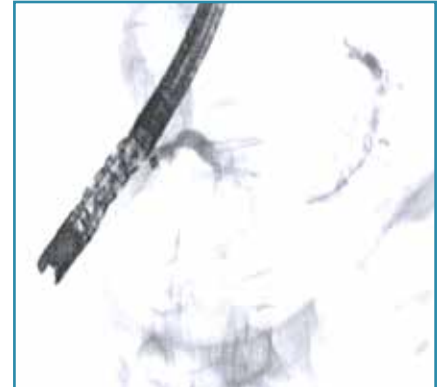


Image 7. ARCHIMEDES biodegradable pancreatic stent, fluoroscopic control of position at the pancreatic duct

Due to the length of the stent (80 mm) and its initial position in the PD, the physician decided to reposition the **ARCHIMEDES** into a more distal position into the duodenum using biopsy forceps. The stent was easily repositioned, demonstrating the excellent handling characteristics of the stent. Physician was happy with the final result, follow-up planned at 1 month and 3 months post-op.

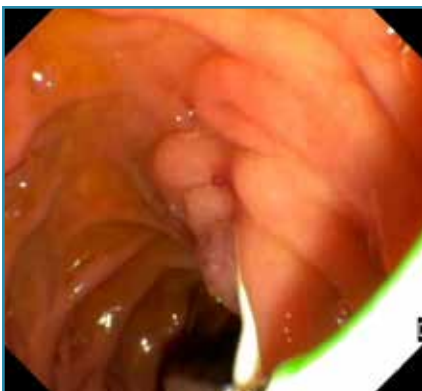

Image 8. ARCHIMEDES biodegradable pancreatic stent being retracted more distally, into the duodenum, for final position

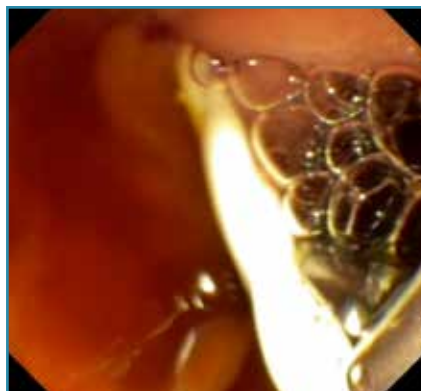


Image 9. ARCHIMEDES biodegradable pancreatic stent being retracted more distally, into the duodenum, for final position

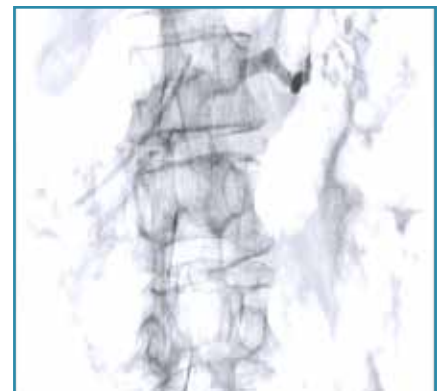

Image 10. Final fluoroscopic view of the ARCHIMEDES biodegradable pancreatic stent implanted

amginternational
A Q3 Medical Company

amg International GmbH | Boschstraße 16 | D-21423 Winsen | Germany

Phone +49 4171 6905 57-0
Fax +49 4171 6905 57-11

Email info@amggastro.com
Web www.amggastro.com

Manufactured by
QualiMed Innovative Medizinprodukte GmbH
Boschstraße 16 | D-21423 Winsen | Germany | www.qualimed.de

Humanitas Case 2
Rev.01 10-2018