

Case Report

Prophylaxis for PEP

University Hospital Virgen de Arrixaca
Murcia, Spain

THE FUTURE IN
BIODEGRADABLE
GI PRODUCTS

ARCHIMEDES

Biodegradable Biliary and Pancreatic Stent



57 y/o female patient from referred from different hospital facility, with previous repeated episodes of pancreatitis, possibly attributed to pancreas divisum. ERCP performed to evaluate and assess for possible sphincterotomy and pancreatic stent placement.

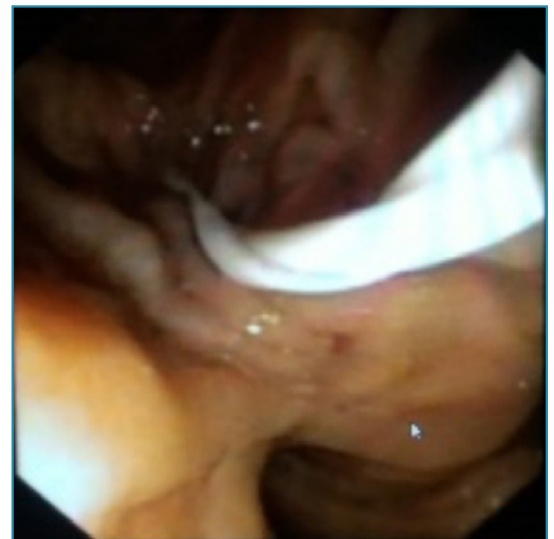

Image 1. Initial of transpapillary positioning of ARCHIMEDES

Under sedation, endoscopist attempted to assess the biliary tree for diagnostic; however, Papilla of Vater was extremely difficult to cannulate due to the presence of some fibrotic tissue. After 20 minutes, the device was exchanged to a thinner 0.021" sphincterotome system; guide-wire was positioned in the biliary duct and contrast injected showing no alterations. No pancreatic duct (PD) suggestive of pancreas divisum, therefore, also no presence of minor papilla.

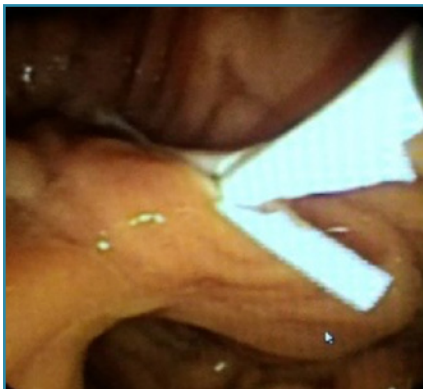


Image 2. Implantation of ARCHIMEDES - view with pusher

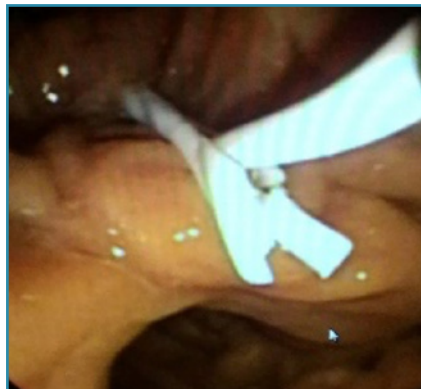

Image 3. Implantation of ARCHIMEDES - view with pusher

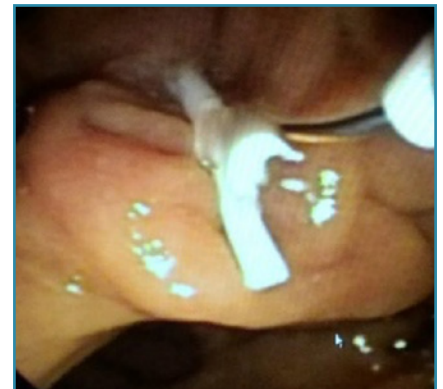


Image 4. Retrieval of pusher, guidewire still in position

Case Report

Prophylaxis for PEP

University Hospital Virgen de Arrixaca
Murcia, Spain

Due to the intense manipulation of the papilla, prophylactic pancreatic stent placement was considered to prevent post-ERCP pancreatitis (PEP). Positioning of the guidewire in the pancreatic duct proved very difficult and an 0.025" guidewire was successfully introduced. An **ARCHIMEDES** biodegradable stent (6 F x 40 mm, fast degradation) was smoothly inserted in the PD in a transpapillary position.

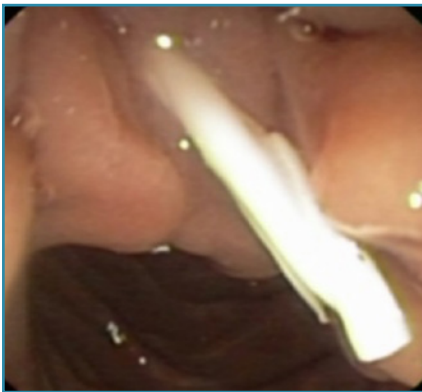

Image 5. Final position of **ARCHIMEDES** biodegradable pancreatic stent

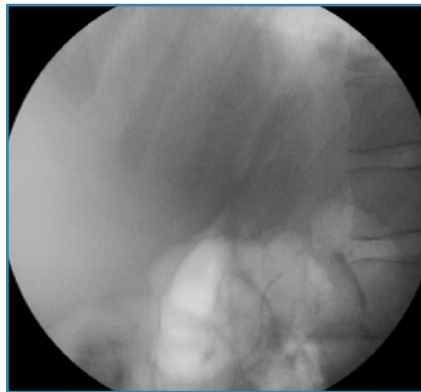


Image 6. Final fluoroscopic view of **ARCHIMEDES** biodegradable stent

The **ARCHIMEDES** biodegradable stent was prepared per the IFU and implanted in the PD, over a 0.025" guidewire, using a 7 F pushing catheter; procedurally similar to the placement of standard plastic stents.

Having the **ARCHIMEDES** biodegradable stent implanted assured that there would be no need for an additional ERCP for a device removal as is the standard with plastic stents.