

Case Report

Hepaticojejunostomy Benign Stricture

University Hospital of Brussels (UZB)
Brussels, Belgium

THE FUTURE IN
BIODEGRADABLE
GI PRODUCTS

ARCHIMEDES

Biodegradable Biliary and Pancreatic Stent



65 y/o male patient with previous resection of the head of the pancreas following pancreatic cancer, had developed a benign stricture at the hepaticojejunostomy just after the position of a partially covered self-expandable metallic stent (PCSEMS), implanted under endoscopic ultrasound (EUS)

The identified stricture had been dilated in previous procedures, in two occasions and the physician believed that implanting a biodegradable stent could contribute to remodeling the duct and the completion of this treatment, while not requiring additional interventions, such as the necessary removal of traditional plastic stents.

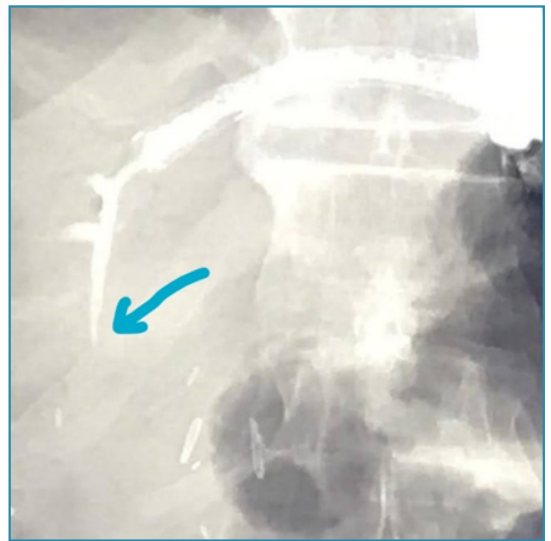


Image 1. Fluoroscopic image showing the benign stricture (blue arrow).

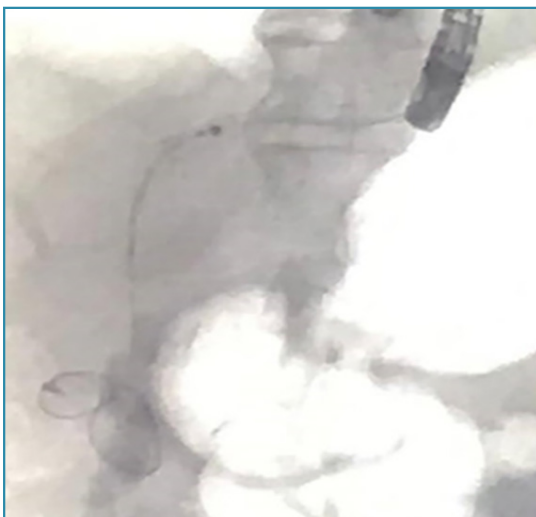


Image 2. Positioning of the stiff guidewire prior to balloon dilatation and stenting.

With the patient under anaesthesia, duodenoscopy was initiated and the antegrade access to the hepatic duct and crossing of the PCSEMS was accomplished without incident. Contrast media was injected to confirm the presence of the stricture and the decision was made to dilate the stricture prior to stent placement.

To ensure a better progression and stability for the balloon catheter and posterior stenting, due to the antegrade access and possible compromise on pushability, a very stiff wire was successfully positioned (Advantage Glidewire 0.035" x 250 cm, Terumo).

An 8 mm x 4 cm biliary dilatation balloon was selected (Hurricane RX, BSCI), positioned in place and stricture was dilated.

Case Report

Hepaticojejunostomy Benign Stricture

University Hospital of Brussels (UZB)
Brussels, Belgium

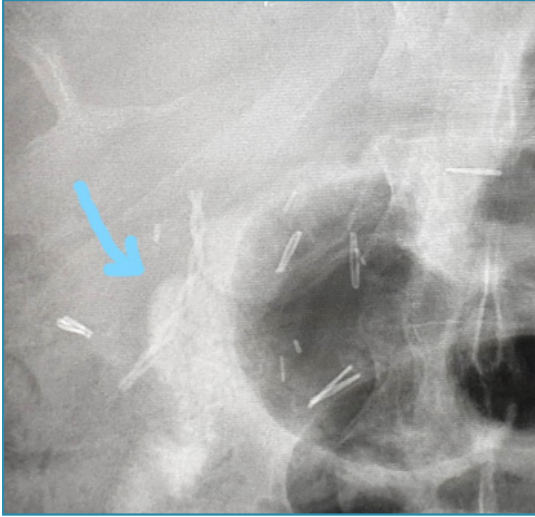


Image 3. Fluoroscopic view of ARCHIMEDES Biodegradable stent, 10F, Slow degradation implanted at the location of the stricture

biodegradable biliary/pancreatic stent in a wide array of indications in both, endoscopic and surgical settings.

After removal of the balloon catheter a 10 F, slow degrading **ARCHIMEDES** Biodegradable biliary/pancreatic stent was introduced over the wire in position, using a 7 F pushing catheter (included in Naviflex system, BSCI). Progression of the stent and crossing of the PCSEMS was very smooth and quick.

Having the possibility to use the **ARCHIMEDES** biodegradable stent in this case, instead of a plastic stent, was very important as there will be no need to re-intervene to retrieve the stent at a later stage.

The case was performed and completed without incident and the physician, a very important, internationally recognised KOL in this field, was very happy with the overall procedure and the performance of **ARCHIMEDES**.

The physician expressed his intention to continue and increase the usage of and research of the **ARCHIMEDES**